

# The Caudal Septum Replacement Graft

Hossam M.T. Foda, MD

**Objective:** To describe a technique for reconstructing the lost tip support in cases involving caudal septal and premaxillary deficiencies.

**Methods:** The study included 120 patients with aesthetic and functional nasal problems resulting from the loss of caudal septal and premaxillary support. An external rhinoplasty approach was performed to reconstruct the lost support using a cartilaginous caudal septum replacement graft and premaxillary augmentation with Mersilene mesh.

**Results:** The majority of cases (75%) involved revisions in patients who had previously undergone 1 or more nasal surgical procedures. A caudal septum replacement graft was combined with premaxillary augmenta-

tion in 93 patients (77.5%). The mean follow-up period was 3 years (range, 1-12 years). The technique succeeded in correcting the external nasal deformities in all patients and resulted in a significant improvement in breathing in 74 patients (86%) with preoperative nasal obstruction. There were no cases of infection, displacement, or extrusion.

**Conclusions:** The caudal septum replacement graft proved to be very effective in restoring the lost tip support in patients with caudal septal deficiency. Combining the graft with premaxillary augmentation using Mersilene mesh helped increase support and stability over long-term follow-up.

*Arch Facial Plast Surg.* 2008;10(3):152-157

**T**HE ROLE OF THE CAUDAL segment of septal cartilage in providing architectural support to the nasal tip was emphasized by Metzenbaum<sup>1</sup> almost 80 years ago. Any loss of that caudal septal support would substantially affect the stability of nasal tip and thereby result in serious aesthetic as well as functional problems.<sup>2</sup> Caudal septal deficiencies may be due to congenital underdevelopment or to acquired factors such as surgical excisions or cartilage destruction by nasal trauma or infections. Many techniques involving caudal septal resections have been described in the literature mainly to achieve superior tip rotation, to shorten the nose, or to correct complex caudal septal deviations.<sup>3-5</sup> However, most of the modern techniques for tip repositioning and caudal septal correction avoid excising any caudal septal cartilage in order to maintain its vital role in supporting the nasal tip.<sup>6-14</sup> Besides direct surgical excision, another cause of caudal septal destruction is external nasal trauma. Severe crush injuries involving the caudal septum or less severe repeated trauma, as in some sports, may ultimately lead to cartilage resorption. Fi-

nally, infections involving the septum may totally destroy the cartilage to the extent of causing septal perforations. Loss of the caudal septal support will result in a weak, unstable tip that can easily be displaced backward and downward by the weight of the thick lobular skin and the constant pull of gravity, leading to loss of tip projection and rotation, which results in a depressed, droopy nasal tip with an acute nasolabial angle and a retracted columella. Caudal septal deficiency is usually associated with variable degrees of premaxillary bone loss due to an underdeveloped, resected, or partially resorbed anterior nasal spine. This article describes a technique for restoring tip support using a cartilaginous caudal septum replacement (CSR) graft (**Figure 1**) and premaxillary augmentation with Mersilene mesh (Ethicon Inc, Somerville, New Jersey).

## METHODS

The study included 120 patients in whom loss of caudal septal and premaxillary support resulted in external nasal deformities with or without nasal obstruction. The deformities included a depressed, droopy nasal tip with an acute nasolabial angle, a retrodisplaced naso-

**Author Affiliation:** Division of Facial Plastic Surgery, Department of Otolaryngology, Alexandria Medical School, Alexandria, Egypt.

labial junction, a posteriorly inclined upper lip, and a retracted columellar base (**Figure 2A** and **C**). Reconstruction in all cases was performed through an external rhinoplasty approach<sup>15</sup> in which bilateral alar marginal incisions are connected via an inverted V-shaped transcolumellar incision, followed by elevation of the columellar skin off the medial crura. Next, the dorsal skin flap elevation is continued in the avascular supraprericartilaginous plane up to the nasion to fully expose the bonycartilaginous framework. The technique of CSR grafting includes 3 steps: (1) preparation of the membranous septum-premaxillary pocket, (2) preparation of the graft, and (3) placement and fixation of the graft. All patients received periodic follow-up, during which periodic clinical examinations and photographic documentation were performed to assess the aesthetic and functional outcomes of the procedure.

### PREPARING THE MEMBRANOUS SEPTUM-PREMAXILLARY POCKET

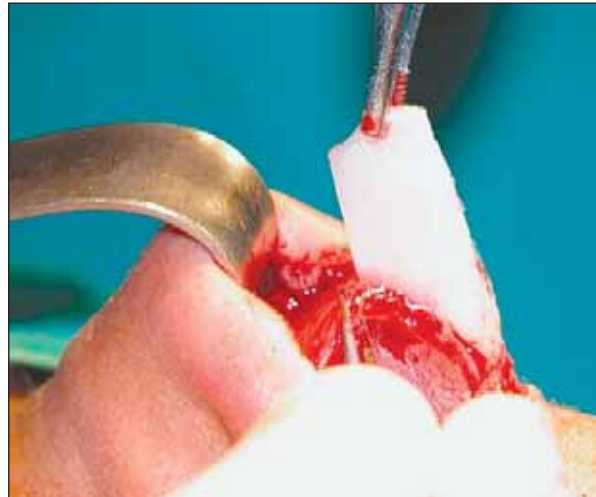Instrument palpation is used to measure how much caudal septum is missing. Occasionally, the membranous septum may be firm on palpation, giving the impression that some cartilage is present, but on exploration, only thick scar tissue caused by previous surgical procedures is found. The medial crura are pulled apart, and the thick scar tissue is excised using sharp dissection with a No. 15 blade. Then, fine tenotomy scissors are used to continue the dissection cephalically, with care being taken to stop a few millimeters before the edge of the remaining septal cartilage is reached, thus keeping the created membranous septal pocket isolated from the septum proper. The dissected pocket is then extended posteriorly between the footplates of the medial crura until it reaches the premaxilla and the anterior nasal spine, which is usually found to be previously resected or partially resorbed. In such cases, dissection is continued on both sides of the spine to create a pocket for premaxillary augmentation. Mersilene mesh is used to augment the premaxilla after being rolled tightly and fixed at the midpoint with a 5/0 silk suture.<sup>16</sup> The roll of mesh is then trimmed to an average length of 2 cm (range, 1-3 cm), and its lateral ends are tapered. The thickness of the roll depends on the extent of the premaxillary deficiency. Next, the prepared roll of mesh is soaked in gentamicin sulfate solution and introduced into the premaxillary pocket, with care being taken to make certain that the silk suture rests strictly in the midline, thereby ensuring central placement of the implant.

### PREPARING THE CSR GRAFT

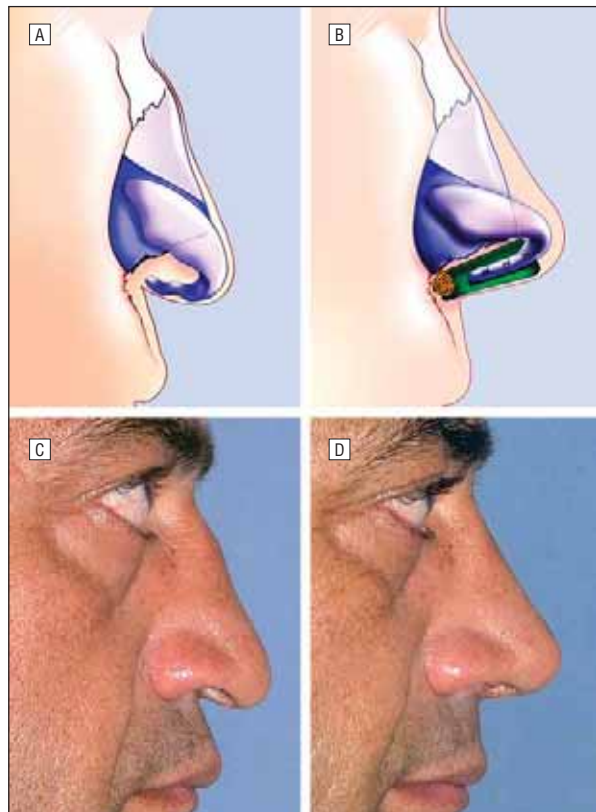
Donor cartilage for the CSR graft can be obtained from multiple sources: the first, and most preferable, choice is autogenous septal cartilage, followed by autogenous conchal cartilage, and then by irradiated costal cartilage homograft. The dimensions of the graft depend mainly on the size of the missing caudal segment and the aesthetic goals of the operation. The length (anteroposterior dimension) of the graft is determined by the amount of tip projection needed; the width (cephalo-caudal dimension) ranges from 7 to 13 mm, depending on the extent of caudal septum deficiency; and the thickness of the graft ranges from 2 to 4 mm for autogenous grafts and from 3 to 6 mm for irradiated cartilage homografts.

#### Septal Cartilage CSR Graft

Most of the cases that require CSR are secondary cases, involving patients who have previously undergone 1 or more nasal surgical procedures. In such cases, the first step, before the septum is injected, is to use instrument palpation on all parts of

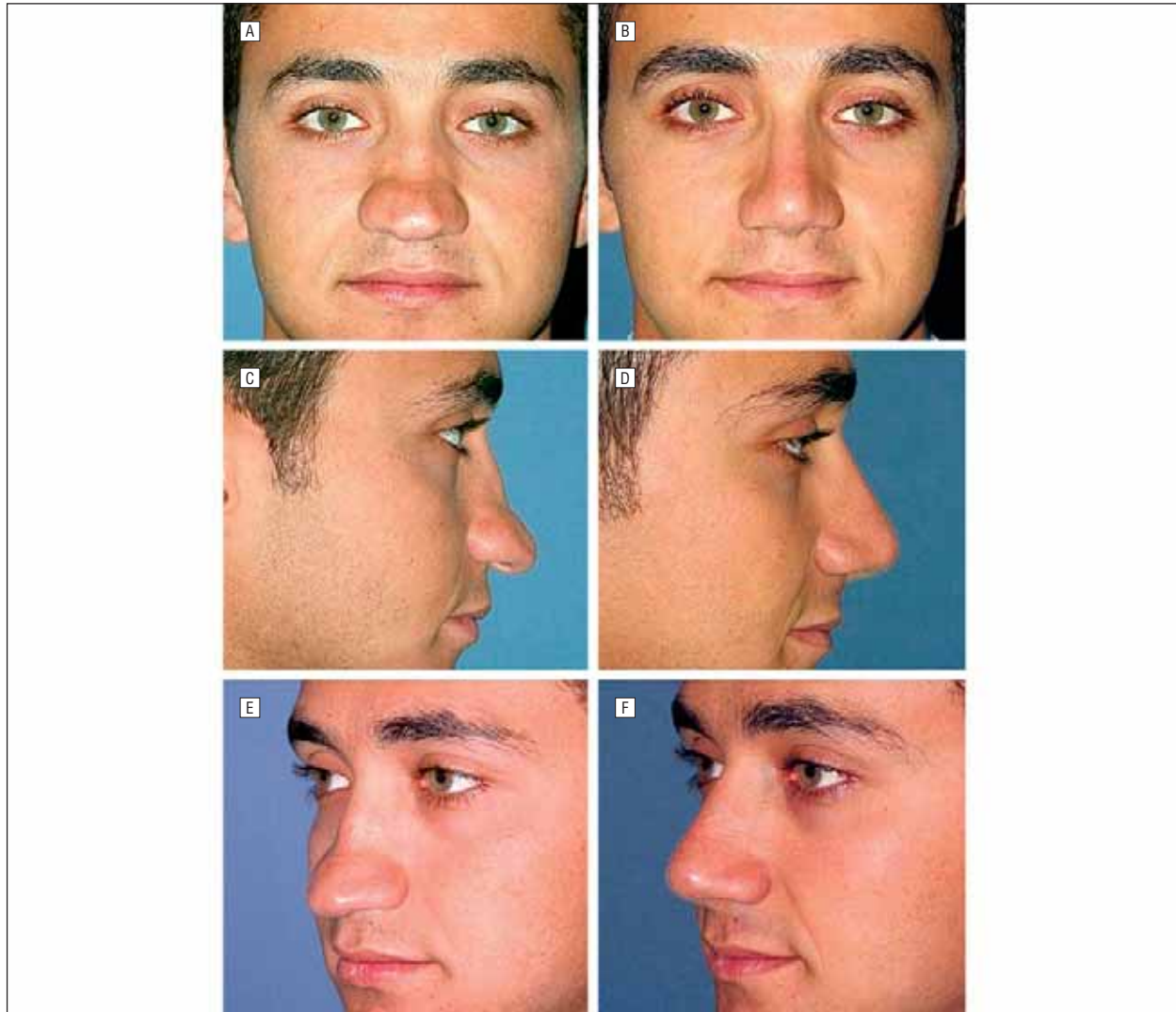


**Figure 1.** Intraoperative view of the caudal septum replacement graft.



**Figure 2.** Revision case. A and C, Preoperative schematic illustration and photograph of a patient with caudal septal and premaxillary deficiency showing a depressed, droopy tip, an acute nasolabial angle, a retrodisplaced nasolabial junction, and a posteriorly inclined upper lip. B and D, The same patient after reconstruction with a caudal septum replacement graft and premaxillary augmentation with a roll of Mersilene mesh.

the septum in order to accurately outline the areas of the missing cartilage. The central portion of the cartilaginous septum is the part that is most commonly missing; in such cases, a more ventral approach is adopted by placing the incision on the side of maxillary crest that extends down to the vestibular floor. The mucoperiosteum is easily elevated off the maxillary crest, and the flap elevation is continued upward to expose the ventral



**Figure 3.** Revision case. A, C, and E, Preoperative views of a patient who previously underwent a septal surgical procedure with resection of the caudal septum and the anterior nasal spine. B, D, and F, Postoperative views of the same patient 28 months after reconstruction with an auricular cartilage caudal septum replacement graft and premaxillary augmentation with Mersilene mesh.

part of the septal cartilage that is attached to the maxillary crest. This is the best part to use for a CSR graft as it is the thickest part of septal cartilage and is usually found intact, even in revision cases with near-total absence of septal cartilage.

#### Conchal Cartilage CSR Graft

The conchal cartilage CSR graft is harvested through an anterior approach using a curved incision parallel to the antihelix, but a few millimeters below it to allow the scar to be hidden by the curve of the antihelix and its inferior crus. The skin and the anterior perichondrium are raised in 1 layer, exposing the entire conchal bowl; then, a No. 15 blade is used to make a full-transfixion incision through the cartilage a few millimeters below and parallel to the antihelical fold and its inferior crus.<sup>17</sup> The conchal cartilage, with its posterior perichondrium attached, is dissected from the postauricular skin until it reaches the external auditory canal, where it is vertically separated half a centimeter behind the posterior canal wall. To change the thin concave conchal cartilage into a thick and straight CSR graft, a vertical partial-thickness cut is made on the concave surface of the cartilage, which is then folded in on itself in a

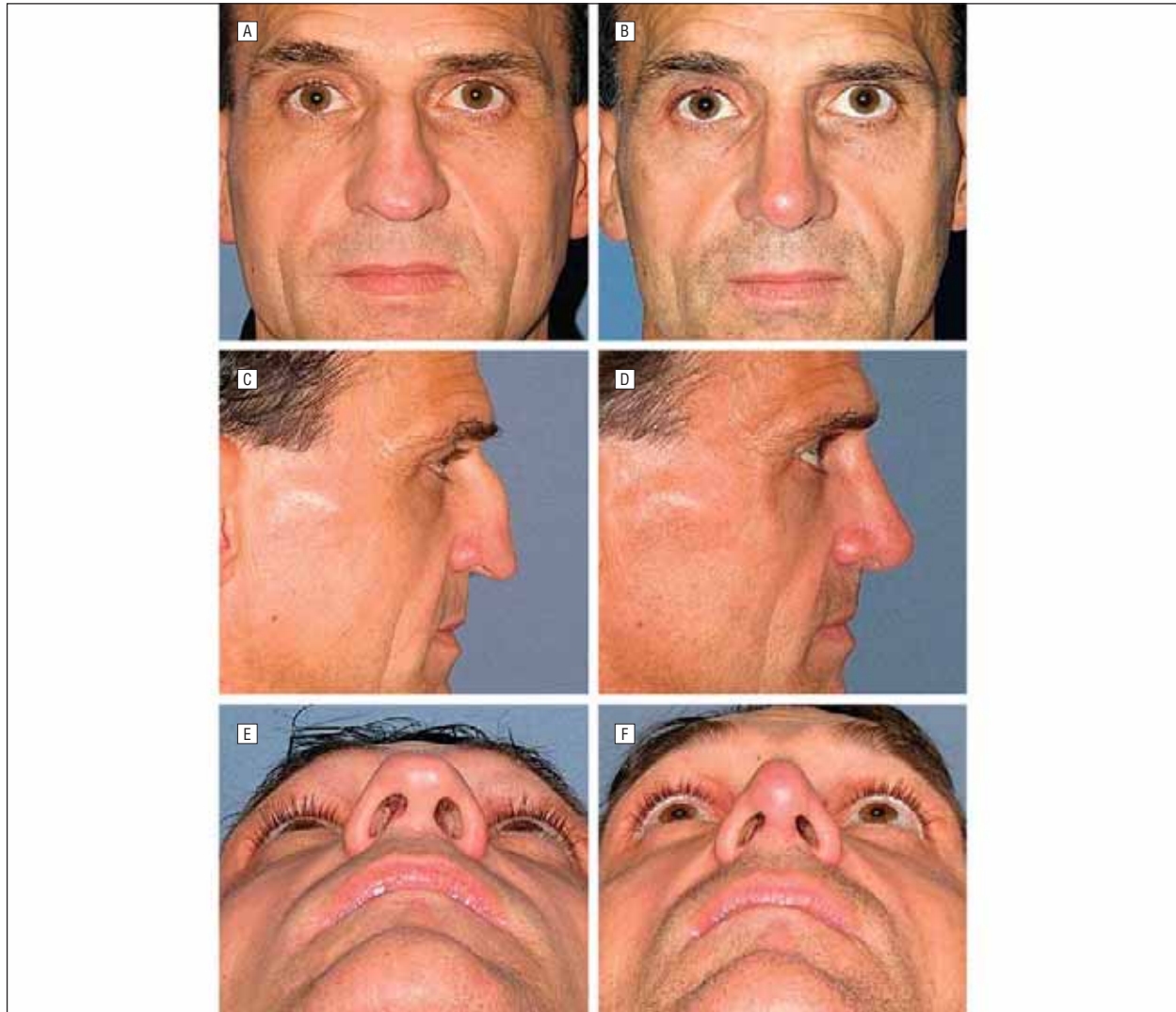
back-to-back fashion and sutured into a double layer using 6/0 polypropylene mattress sutures.

#### Irradiated Costal Cartilage CSR Graft

An irradiated costal cartilage CSR graft is generally used only when no usable septal or conchal cartilage can be found. It is fashioned to be approximately 50% thicker than the autogenous graft. To avoid excessive widening of the columella, the thinner inferior margin of the rib is used as the caudal margin of the graft; then, the graft gets gradually thicker in its cephalic part. The perichondrium is kept intact on both surfaces of, at least, the caudal half of the graft to avoid any risk of warping, and any required thinning of the cephalic part is done in a symmetrical and balanced fashion.

#### PLACEMENT AND FIXATION OF THE CSR GRAFT

The base of the graft is beveled in a concave fashion to accommodate the roll of Mersilene mesh. The caudal border of the graft is left longer than the cephalic one (Figure 2B) to pre-



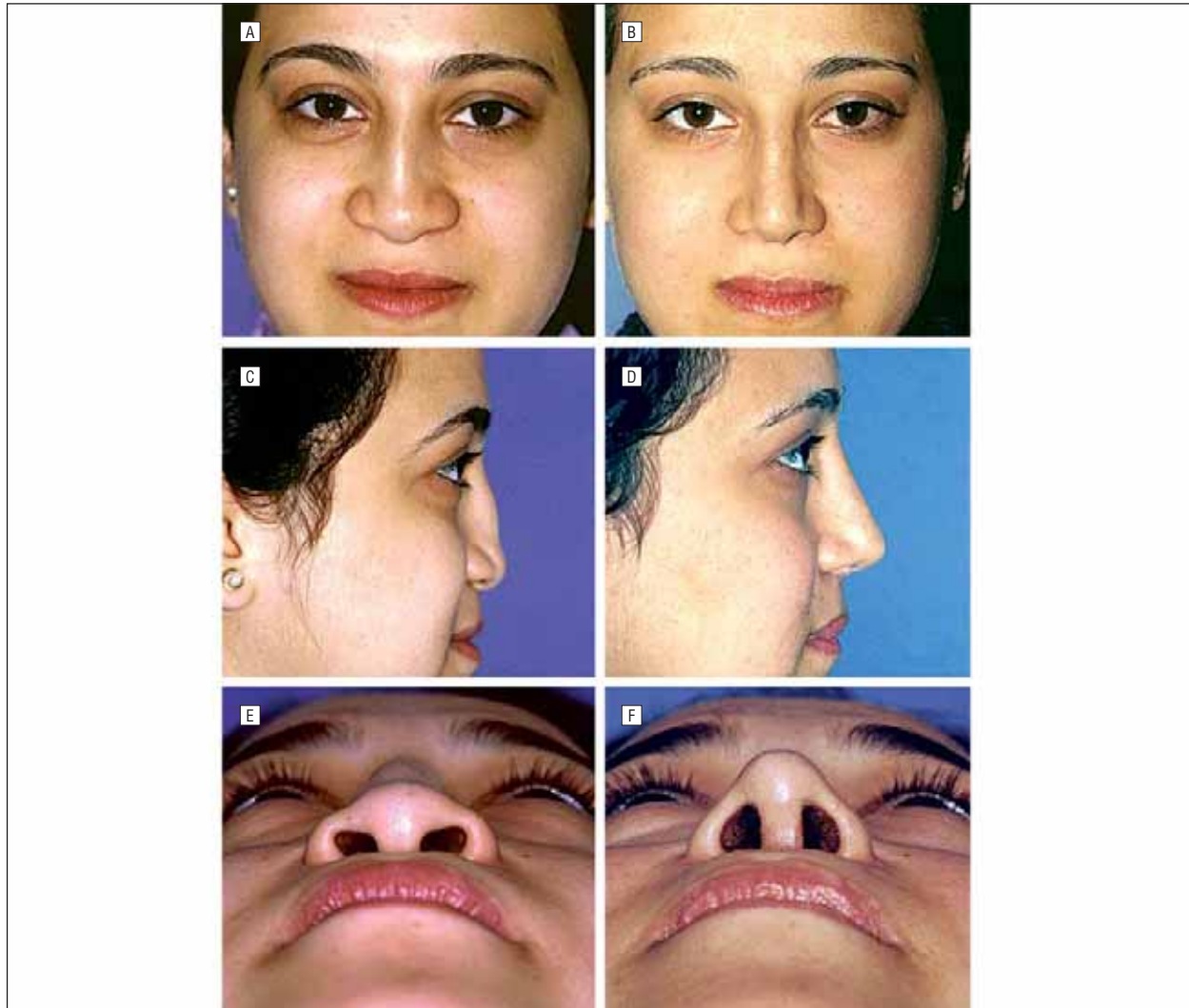**Figure 4.** Revision case. A, C, and E, Preoperative views of a revision patient who previously underwent a previous septal surgical procedure complicated by abscess formation that destroyed the caudal septum. B, D, and F, Postoperative views of the same patient 1 year after reconstruction with a septal cartilage caudal septum replacement graft and premaxillary augmentation with Mersilene mesh.

vent any upward displacement of the graft. The graft is then introduced into the membranous septum pocket and pushed downward until it is tightly pressed against the premaxillary mesh. The graft is fixed in that position to the medial crura with 5/0 polypropylene sutures in a horizontal mattress fashion. Three sutures are used: the first at the level of the medial crural footplates; the second in the columellar segment of medial crura; and the third in the lobular segment of the medial crura (Figure 2B). Finally, the degree of tip projection is assessed, and any excess length of the graft is trimmed to allow approximation of domes to be done above the level of the anterior end of the graft.

## RESULTS

The present study included 120 patients (79 males and 41 females), with a mean age of 29½ years (age range, 16-58 years). Caudal septal cartilage deficiency was present in all cases and was associated with premaxillary bone loss in 93 cases (77.5%). Of the 120 cases, 90 (75%) were

revision cases involving patients who had previously undergone 1 or more rhinoplastic or septal surgical procedures and 30 (25%) were primary cases. In more than 90% (n=82) of the revision cases, the caudal septal and premaxillary deficiencies resulted directly from previous resections (Figure 3), and in fewer than 10% (n=8) of the revision cases, the surgery was complicated by septal hematoma and abscess formation that destroyed the caudal septal cartilage (Figure 4). In 18 of the 30 primary cases (60%), the caudal septal and premaxillary deficiencies resulted from crushing injuries, and in the remaining 12 cases (40%), the deficiency resulted from a congenitally weak underdeveloped caudal septum and premaxilla. Of the 12 cases, 8 involved flat “negroid” noses, and 4 were Binder syndrome (Figure 5). All patients had external nasal deformities, related to the loss of caudal septal and premaxillary support, in the form of a depressed, droopy nasal tip with an acute nasolabial angle, a retrodisplaced nasolabial junction, a posteri-



**Figure 5.** Primary case. A, C, and E, Preoperative views of a patient with a congenitally underdeveloped caudal septum and premaxilla as a result of Binder syndrome. B, D, and F, Postoperative views of the same patient 3 years after caudal reconstruction with an irradiated costal cartilage homograft and premaxillary augmentation.

only inclined upper lip, and a hidden posterior columella. Also, 86 patients (71.7%) had nasal obstruction that was caused by the depressed, droopy nasal tip. A cartilaginous caudal septum replacement graft was used in all 120 patients, and it was combined with premaxillary augmentation with Mersilene mesh in 93 patients (77.5%). The graft was made of autogenous septal cartilage in 63 patients (52.5%), autogenous conchal cartilage in 30 patients (25%), and irradiated costal cartilage homograft in 27 patients (22.5%). All patients received periodic follow-up care for a mean period of 3 years (range, 1-12 years), during which subjective assessment of the outcome of the surgical procedure was performed by clinical examination, by comparison of preoperative and postoperative photographs, and by recording the degree of the patients' satisfaction with their aesthetic and functional results. The CSR graft and premaxillary augmentation corrected the external aesthetic deformities in all cases and provided an excellent amount of support to the nasal tip, allowing it to maintain its position over the long-

term follow-up period, with no loss in the degree of projection or rotation achieved. No cases of infection, displacement, or extrusion were encountered during the follow-up period. Functionally, 74 patients (86%) with preoperative nasal obstruction reported a marked improvement in breathing, and 12 patients (14%) reported no noticeable change in breathing.

#### COMMENT

In any rhinoplasty procedure, a strong tip support is essential to maintain the achieved degree of nasal tip projection and rotation; in other words, the long-term result of any tip-modifying technique will depend mainly on the amount of tip support available. One of the major challenges in rhinoplasty is to provide adequate tip support in cases in which the caudal septum was previously excised or is congenitally deficient. Many types of grafts and implants to replace the missing caudal sep-

tum have been described in the literature.<sup>18-24</sup> The CSR graft used in this study was designed to closely match the shape, consistency, and strength of the missing caudal septum. Therefore, the first and most preferable choice was to fashion the CSR graft from the remaining parts of the patient's own septal cartilage. In the absence of septal cartilage and in cases involving septal perforations,<sup>25</sup> the second choice was to use conchal cartilage, although it is naturally curved, thinner, and less rigid than the septal cartilage. To overcome these disadvantages, the harvested conchal cartilage was folded in on itself and sutured together with permanent sutures to create a more rigid double-layered straight graft. Finally, in the absence of septal and conchal cartilage, the irradiated costal cartilage homograft proved to be a good alternative as it is readily available and incurs no donor-site morbidity. The risk of warping of costal cartilage was not encountered in any of the present cases, mainly because the perichondrium was left intact on both sides of the graft for at least its caudal half, and any required thinning of the cephalic part was done in a symmetrical balanced fashion, as recommended by Gibson and Davis.<sup>26</sup> When irradiated cartilage was used, the graft was kept 50% thicker than the autogenous grafts to make up for any higher resorption rate that might be associated with the use of homografts. All cartilage grafts, whether autogenous or homografts, undergo some degree of resorption, and the amount of graft bulk loss is unpredictable.<sup>19,27</sup> However, the higher the tension on the graft, the more resorption there is; therefore, the CSR graft is always designed to be thicker and larger in patients with thick, heavy nasal skin.

In the current study, most cases of caudal septal deficiency (77.5%) were associated with some degree of premaxillary deficiency in which the premaxilla and/or the anterior nasal spine was found to be underdeveloped, previously resected, or partially resorbed. In such cases, premaxillary augmentation should be performed before any caudal septal reconstruction is attempted. In my experience, Mersilene mesh is an ideal augmentation material for the premaxilla.<sup>16</sup> It is soft and pliable, and its latticelike structure allows host tissue ingrowth that leads to early fixation of the implant. The presence of the roll of mesh in the premaxilla has proved to be very helpful to the CSR graft. The roll of mesh provides a soft cushion on which the base of the CSR graft will rest, thus stabilizing the graft and preventing any side-to-side movement that might cause a "click" against the premaxillary bone. Another advantage of the roll of mesh is that it guards against any upward displacement of the graft, thus avoiding potential overriding between the inserted graft and the septum. Also, leaving a few millimeters of membranous septum undissected will prevent any direct contact between the graft and the caudal edge of the remaining septum. This intact part allows preservation of some of the natural mobility of nasal lobule. This mobility is usually lost with other methods in which the graft is fixed to the nasal septum either by direct suturing or by cartilage grafts,<sup>21,28-31</sup> leading to an unnaturally stiff nasal lobule.

Accepted for Publication: February 25, 2008.

Correspondence: Hossam M.T. Foda, MD, Division of Facial Plastic Surgery, Department of Otolaryngology,

Alexandria Medical School, PO Box 372 Sidi Gaber, Alexandria, Egypt (hfoda@dataxprs.com.eg).

Financial Disclosure: None reported.

## REFERENCES

- Metzenbaum M. Replacement of the lower end of the dislocated septal cartilage versus submucous resection of the dislocated end of the septal cartilage. *Arch Otolaryngol*. 1929;9:285-296.
- Foda HMT. Rhinoplasty for the multiply revised nose. *Am J Otolaryngol*. 2005;26(1):28-34.
- Parkes ML, Brennan HG. High septal transfixion to shorten the nose. *Plast Reconstr Surg*. 1970;45(5):487-492.
- Wexler MR. Reconstructive surgery of the injured nose. *Otolaryngol Clin North Am*. 1975;8(3):663-677.
- Peck GC. Basic primary rhinoplasty. *Clin Plast Surg*. 1988;15(1):15-27.
- Adamson PA, Tropper GJ, McGraw BL. The hanging columella. *J Otolaryngol*. 1990;19(5):319-323.
- Tebbetts JB. Shaping and positioning the nasal tip without structural disruption. *Plast Reconstr Surg*. 1994;94(1):61-77.
- Gunter JP, Rohrich RJ. Management of the deviated nose: the importance of septal reconstruction. *Clin Plast Surg*. 1988;15(1):43-56.
- Kridel RWH, Scott BA, Foda HMT. The tongue-in-groove technique in septorhinoplasty. *Arch Facial Plast Surg*. 1999;1(4):246-256.
- Foda HMT, Kridel RWH. Lateral crural steal and lateral crural overlay: an objective evaluation. *Arch Otolaryngol Head Neck Surg*. 1999;125(12):1365-1370.
- Foda HMT, Bassyouni K. Rhinoplasty in unilateral cleftlip nasal deformity. *J Laryngol Otol*. 2000;114(3):189-193.
- Foda HMT. Alar setback technique: a controlled method of nasal tip deprojection. *Arch Otolaryngol Head Neck Surg*. 2001;127(11):1341-1346.
- Foda HMT. Management of the droopy tip: a comparison of three alar cartilage-modifying techniques. *Plast Reconstr Surg*. 2003;112(5):1408-1417.
- Foda HMT. The role of septal surgery in management of the deviated nose. *Plast Reconstr Surg*. 2005;115(2):406-415.
- Foda HMT. External rhinoplasty in the Arabian nose: a columellar scar analysis. *Aesthetic Plast Surg*. 2004;28(5):312-316.
- Foda HMT. Mersilene mesh in premaxillary augmentation. *Aesthetic Plast Surg*. 2005;29(3):169-173.
- Foda HMT. Otoplasty: a graduated approach. *Aesthetic Plast Surg*. 1999;23(6):407-419.
- Slavit DH, Bansberg SF, Facer GW, Kern EB. Reconstruction of caudal end of septum: a case for transplantation. *Arch Otolaryngol Head Neck Surg*. 1995;121(10):1091-1098.
- Kridel RWH, Konior RJ. Irradiated cartilage grafts in the nose: a preliminary report. *Arch Otolaryngol Head Neck Surg*. 1993;119(1):24-31.
- Neu BR. Combined conchal cartilage-ethmoidal bone grafts in nasal surgery. *Plast Reconstr Surg*. 2000;106(1):171-175.
- Pirsig W, Kern EB, Verse T. Reconstruction of anterior nasal septum: back-to-back autogenous ear cartilage graft. *Laryngoscope*. 2004;114(4):627-638.
- Nolste Trenite GJ. Grafts in nasal surgery. In: *Rhinoplasty: A Practical Guide to Functional and Aesthetic Surgery of the Nose*. Amsterdam, the Netherlands: Kugler Publications; 1993:45-56.
- Jang YT. Surgery of nasal tip. In: Jang YJ, Park CH, eds. *Practical Septorhinoplasty: An Asian Perspective*. Seoul, Korea: Koonja Publishing Inc; 2007:275-334.
- Kridel RWH, Lunde K. Nasal septal reconstruction: review and update. *Facial Plast Surg Clin North Am*. 1999;7(1):105-113.
- Foda HMT, Magdy EA. Combining rhinoplasty with septal perforation repair. *Facial Plast Surg*. 2006;22(4):281-288.
- Gibson T, Davis WB. The distortion of autogenous cartilage: its cause and prevention. *Br J Plast Surg*. 1958;10:257-274.
- Gibson T, Curran RC, Davis WB. The survival of living homograft cartilage in man. *Transplant Bull*. 1957;4(3):105-106.
- Meyer R, Kesselring UK. Surgical correction of the unusually short nose. *Aesthetic Plast Surg*. 1977;1:271-277.
- Naficy S, Baker SR. Lengthening the short nose. *Arch Otolaryngol Head Neck Surg*. 1998;124(7):809-813.
- Gruber RP. Surgical correction of short nose. *Aesthetic Plast Surg*. 2002;26(suppl 1):6.
- Guyuron B, Verghai A. Lengthening the nose with a tongue-and-groove technique. *Plast Reconstr Surg*. 2003;111(4):1533-1539.